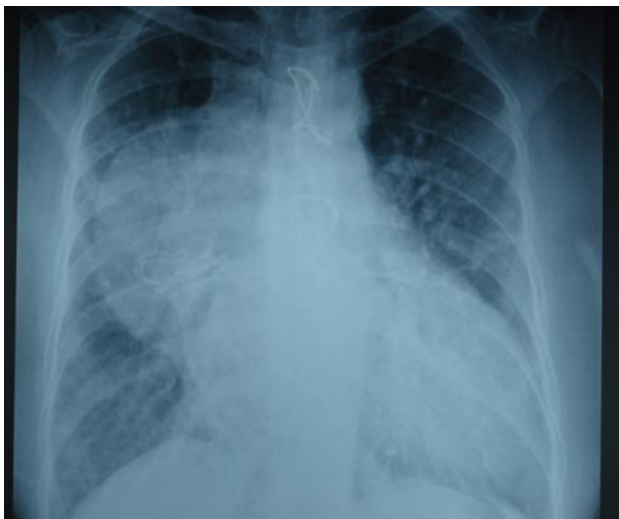
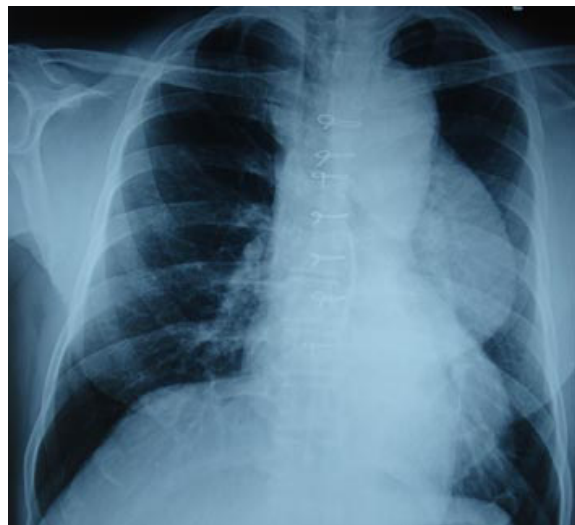

These are the Chest X ray of 3 different patients presenting with chest discomfort & dyspnoea with different diagnosis; guess the diagnoses?

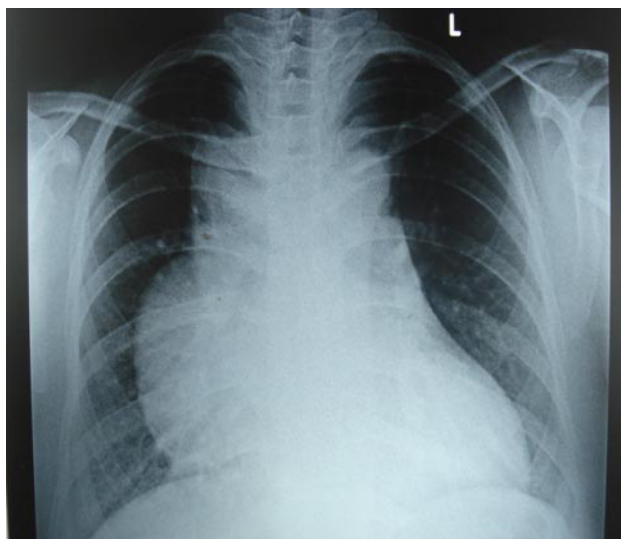
1. 50 yr.old lady h/o CABG 3 yrs back



2. 78 yr.old gentleman/o CABG 12 yrs.back

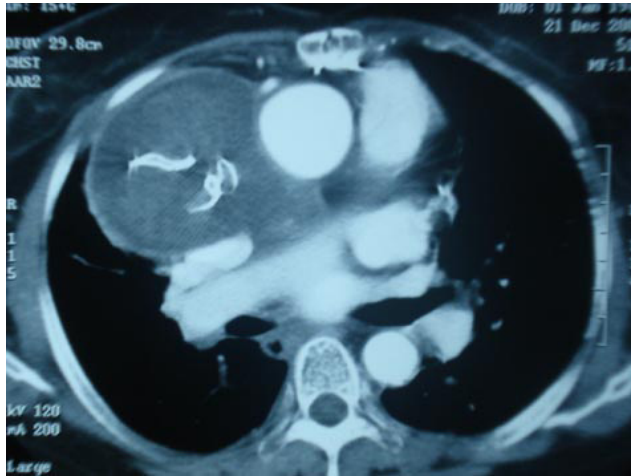


3. Lady in the early 40s

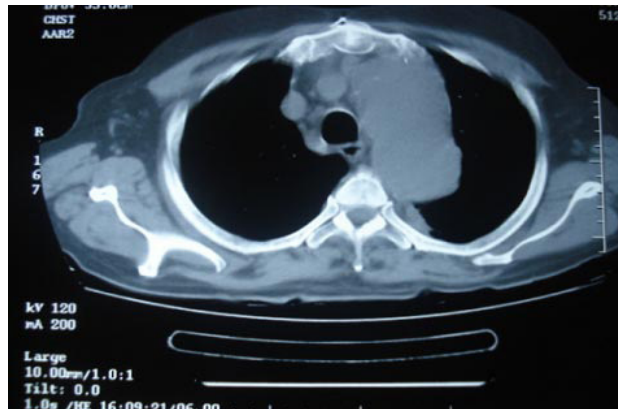


Answers:

1. Metal wires induced irritant pleurisy - Mediastinal encysted pleural effusion



2. Aortic Aneurysm



3. Anterior mediastinal mass - Thymoma

