
Askin Tumour masquerading as pleural effusion in young

Anoop M.P*, Baiju C*, Krishna Kumar*, Sunny George**,
Santhosh Kumar P.V***, P.T. James****

*PG resident, **Senior Lecturer, ***Assistant Professor, ****Professor,
Institute of Chest Diseases, Medical College, Calicut.

Key words;

Askin's tumor, Pleural effusion

Abbreviations: PNET – Primitive Neuroectodermal tumor, BPAD - Bipolar affective disorder, RTA - Road traffic accident, RT – Radiotherapy, CT - Chemotherapy.

Abstract

Malignancy in a young individual is always alarming. Malignant pulmonary neoplasms in younger age groups pose diagnostic dilemmas for the physician and an unacceptable situation for the patient & relatives.

This is a case report of a 27 year old male on treatment for Bipolar affective disorder presenting clinically with features of right pleural effusion. Subsequently on work up was detected to have malignant small round cell tumor of chest wall.

Case summary

A 27 year old male presented with complaints of progressive dyspnoea on exertion Grade I to III, dry cough, and right sided pleuritic type of chest pain persisting as dull aching chest pain radiating to back of 3 weeks duration.

Low-grade fever, Loss of weight of about 2 kg and loss of appetite was present.

He was an auto driver by profession & gave history of RTA 3 months back with trauma to thorax which was managed conservatively. He belonged to a broken family & was supported by his relatives. He is a smoker with a smoking score of 40. He also gave history of promiscuous sexual habits including homosexual behaviour.

He was on treatment for BPAD with Lithium and Divalproex Sodium for 4 years. He was treated with antibiotics by a local physician for present complaints and his initial chest X ray showed right lower zone opacity with a positive extra pleural sign (fig.1). He however did not have any symptomatic improvement and was hence referred after 2 weeks of antibiotics.

When he was admitted to our hospital he clinically had findings of right moderate effusion. His chest X ray on admission was consistent with effusion with another opacity with a convex border merging with the homogenous opacity of effusion. (fig.2).

He was subjected to thoracocentesis and 10 cc of straw-coloured fluid was aspirated. Total count of the fluid

was 3000 cells/mm³ which was lymphocyte predominant (N₈ L₉₂), exudates with high protein (5.3g/dl), low sugar (36 mg/dl) and an ADA of 40 units. His mantoux was 10mm.

Considering the possibility of a tuberculous effusion patient was put on Anti tuberculous medications. Patient could not be admitted any further to watch the response of ATT as bystanders requested discharge considering the patient's psychiatric disturbances.

Two weeks later patient was having symptoms of restlessness (akathisia). Clinically & Radiologically pleural effusion had increased (fig 3). Bystanders were not willing for admission, hence CT was advised.

CT reported bilateral pleural effusion with large encysted effusion on the right side containing irregular soft tissue density components within the right pleural fluid. Nodular lesion noted in anterior segment of right upper lobe. (fig.4)

Patient was advised admission; he was complaining of insomnia and chest pain. Clinically he had pallor; he was dyspneic, tachypneic and had tachycardia. By this time he had developed an axillary chest wall swelling in addition to features of right sided massive effusion (fig.5). Features of extra pyramidal side effects were present. Psychiatry consultation was done. Patient improved symptomatically in terms of restlessness with benzhexol, lorazepam. Regular drugs dosage was reduced.

His blood routine examination revealed a Hemoglobin of 8.5gm%, TC 7600cells/mm³, DC P80L18E2, ESR 120mm/hr. Peripheral smear Neutrophilia shift to (L) and polychromasia. A repeat pleural fluid aspiration yielded 40ml of hemorrhagic fluid. Cytology was inconclusive. PCV-0.7%.

FNAC from chest wall swelling came as Askin's Tumor/Leukemic infiltration. USG Abdomen was normal.

Pleural biopsy came as Askin's Tumor (fig.6).

Oncology opinion was sought and they advised combined RT/CT. Treatment was deferred by the patient's

relatives. Unfortunately the patient succumbed to his illness after 4 weeks.

Discussion

Askin's tumour was first described by Askin in 1974.² Askin's Tumour (Malignant Small round cell tumour of thoracopulmonary region or primitive neuroectodermal tumour of the chest wall, PNET) is a very rare tumour with very few case reports.¹

PNET includes Ewing's sarcoma which are more undifferentiated, soft tissue tumors having better neuroectodermal differentiation.¹ Tumour may arise anywhere, but most commonly affect periosteum and soft tissue of the thoracic wall usually pleural or the extra pleural intercostal soft tissue. Believed to be derived from cells originating in the neural crest. Most commonly children, adolescent and young adults are affected. Male predilection is seen as was the case of our interest³. If tumor is originating from the intercostal nerve female predilection is said to be noted.⁴ PNET are a group of clinically aggressive neoplasm histologically showing small round cells arranged in a lobular pattern and associated with rosettes or pseudorosettes which has immunohistochemical and ultrastructural evidence of neural differentiation. Small round cells contain cytoplasmic glycogen arranged in a peritheliomatous pattern (may or may not contain glycogen, may be PAS+). Tumor has strong immunoreactivity for CD99. Chromosomal translocation responsible are 11:22(q24;q12). 'fli' gene on chromosome 11 with 'cws' gene on 22 detected with RT-PCR or FISH

Other markers are synaptophysin, S100protein, Vimentin, NSE (Neuron specific enolase), Secretogranin (II).

Immunohistochemistry and cytogenetics are important diagnostic features. If they are easily detectable then the course of the tumour is likely to be more aggressive.

There are case reports of tumour developing after radiation for Hodgkin's disease.³

Clinical Features

Chest wall pain is the usual presenting symptoms. Asymptomatic mass in chest wall complicated by pleural effusion, dyspnoea and cough³.

Radiological features are unilateral chest wall mass, Rib destruction, pleural thickening or effusion, soft tissue extension into adjacent lung, pulmonary nodules, occasional mediastinal lymph node enlargement² Calcification is noted occasionally.⁷

Important differential diagnosis are embryonal and alveolar rhabdomyosarcoma, Malignant lymphoma, desmoplastic small cell tumour, Neuroblastoma, Metastatic pulmonary small cell carcinoma.²

Staging by National Cancer institute for Management is as follows:

Stage I tumor - Measuring more than 5cm and can be completely excised

Stage II tumor – Smaller than 5cm in diameter and grossly resectable but show microscopic margins.

Stage III tumor - greater than 5cm in maximum diameter and not resectable.

Stage IV tumor – Metastasis to extra pulmonary sites.

Treatments proposed are,

Low stage – Surgery + RT + CT

Stage III & IV - RT + CT²

Chemotherapy includes cycles with cyclophosphamide, actinomycin, Vincristine, Doxorubicin.⁸

Roscovitine is a new drug in phase II trials used for inducing apoptosis in Ewing's sarcomas tumours¹⁰ which is speculated to be a useful drug in Askin's as well. With surgery prognosis is improved in case reports.^{3,9} Overall 2yr survival in 38 patients was 38%. In another review 5 year survival noted was 25%².

Our patient had all these clinical features; an interesting aspect was its bilateral involvement (Thoracopleuro pulmonary Tumor) and above all its aggressive clinical course.

References

1. Rosai and Ackerman's Surgical pathology Pg 2172
2. Fraser And Pare's diseases of the chest 4th edition pg 3028
3. Comprehensive Text book of Thoracic Oncology pg 832 Aisner, Arrigada
4. Askin AB, Rosai J, Sibley Ak et al Cancer 43:2438, 1979.
5. Israel MA, Williams C.J, Krikorian JG, Text book of uncommon Cancer Peripheral neuroepithelioma , New York, John Wiley 1988:683 – 690
6. Oxford Text book of oncology 2049-50,
7. Grainger and Allison's Text book of Medical imaging 4th edition
8. T. Annals of oncology 6:395-401, 1995
M. Vonschlippe x J.S.cohelan
9. Harrison's principles of internal Medicine 16th edition Pg 561
10. Cancers. aacrjournals.org/cgi/content
L11 65/209320

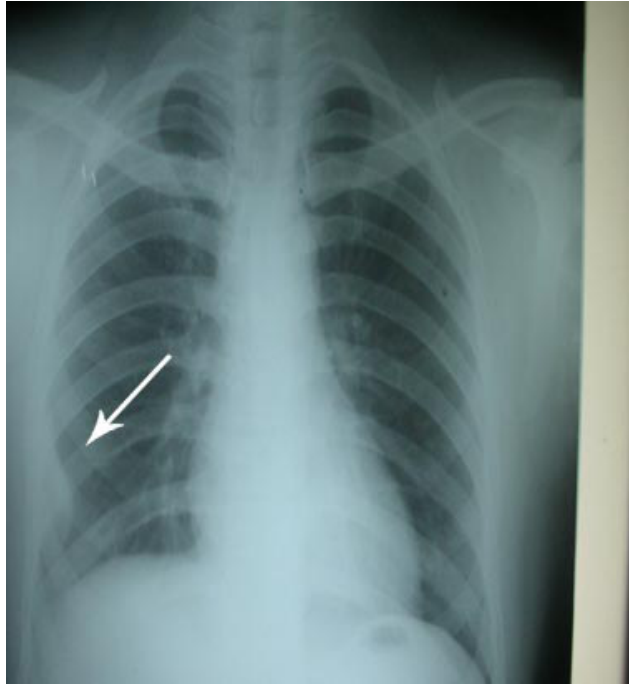


Figure 1

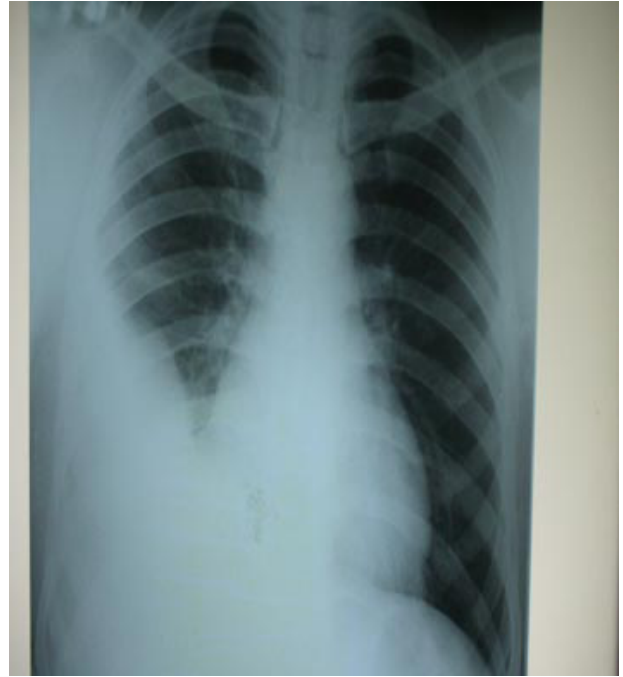

Figure 2

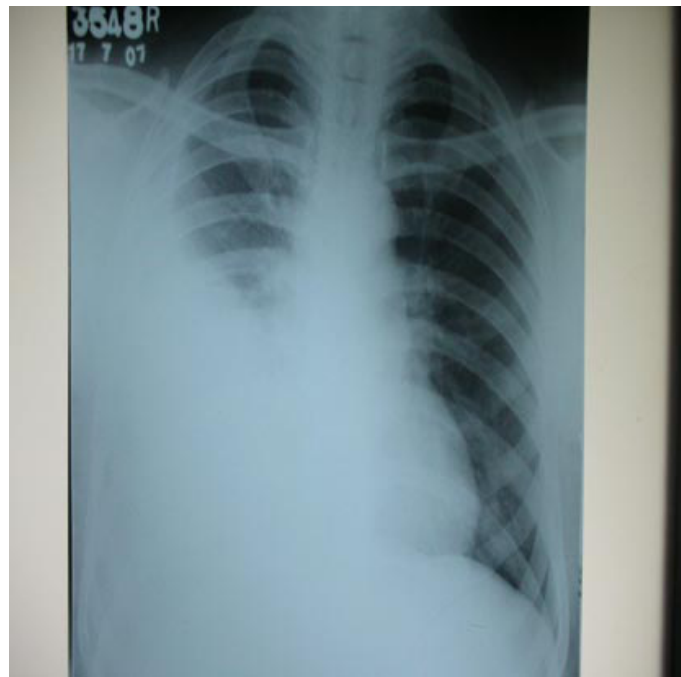


Figure 3

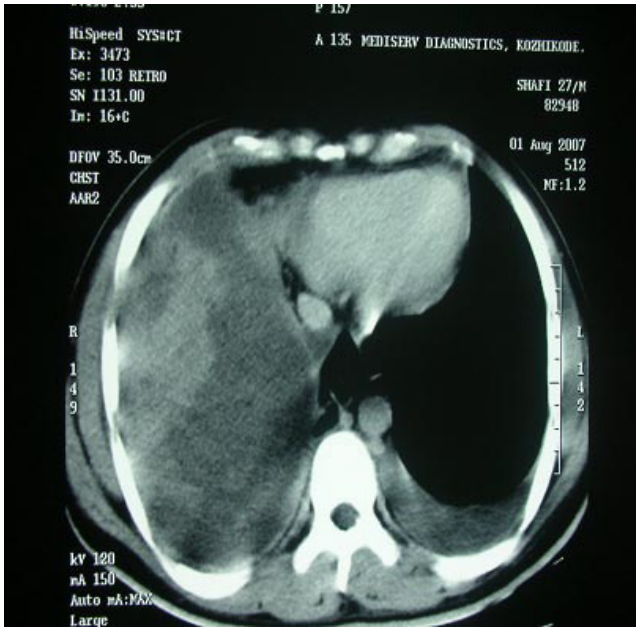


Figure 4

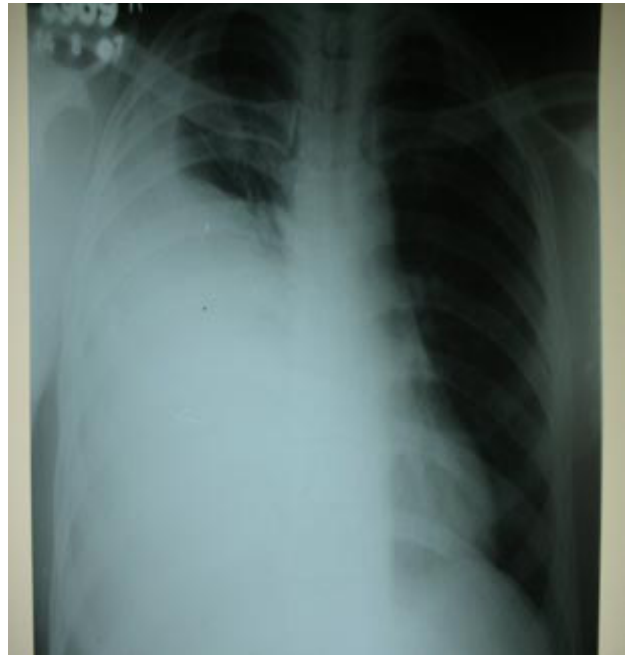


Figure 5

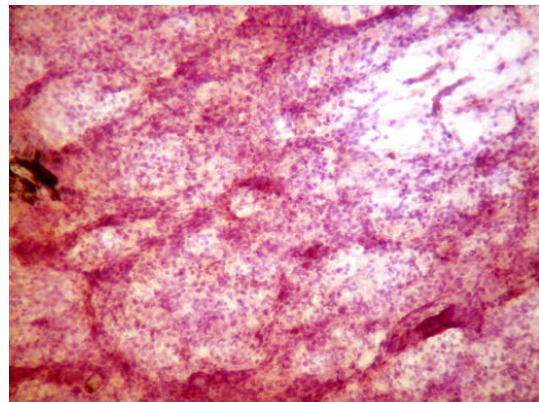
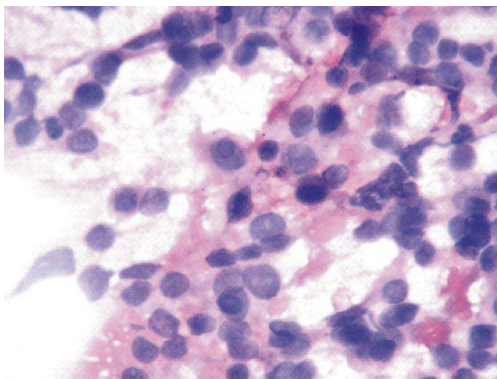


Figure 6